

# Effect of a Xenogeneic Urinary Bladder Injectable Bioscaffold on Lameness in Dogs with Osteoarthritis of the Coxofemoral Joint (Hip): A randomized, Double Blinded Controlled Trial

William Rose, DVM<sup>1</sup>  
Jeffrey D. Wood, DVM<sup>2</sup>  
Abby Simmons-Byrd, RVT<sup>3</sup>  
Alan R. Spievack, MD<sup>4</sup>

<sup>1</sup>Lakeland Veterinary  
Perham, MN 56573

<sup>2</sup>Northside Veterinary Hospital  
Hillsdale, MI, 49242

<sup>3</sup>ACell, Inc.  
Lafayette, IN, 47904

<sup>4</sup>ACell, Inc.  
Columbia, MD 21046

**KEY WORDS:** Osteoarthritis, Dogs, Cyclooxygenase and 5-Lipoxygenase, FlexileRx, Dual Inhibitor, Limbrel, Medical Food

## **ABSTRACT**

More than 20% of all dogs in the United States suffer from lameness and pain associated with chronic osteoarthritis (OA). Many times the current therapeutic modalities are not well tolerated by the pet leaving, few choices for alleviating suffering. Regenerative medicine brings new modalities that may aid dogs that either do not respond to or cannot tolerate traditional therapy. The present study evaluated the efficacy of porcine urinary bladder extracellular matrix (UBM-ECM), an acellular bio-inductive scaffold, to treat dogs with osteoarthritis of the hip joint. This study demonstrates that a single intra-articular injection of UBM-ECM significantly improved activity, lameness, and range of motion scores compared to control dogs. This is the first randomized controlled

clinical trial reporting the effectiveness of a bioinductive scaffold in dogs with OA.

## **INTRODUCTION**

More than 20%, or 10 to 12 million dogs, in the United States are afflicted with OA, making it the most common cause of chronic pain in the dog.<sup>1-3</sup> OA is characterized by degeneration of the articular cartilage surface, matrix loss, fibrillation and formation of fissures that can result in complete loss of the cartilage surface, and significant pain.<sup>4</sup> Chondrocytes are responsible for maintaining a balance between synthesis and degradation of the extracellular matrix, which they accomplish through the secretion of macromolecular components (collagen, glycosaminoglycans, and hyaluronic acid), and through modulation of the extracellular matrix turnover. Chondrocytes secrete tissue-damaging mediators (cytokines, free radicals, proteases, and prostaglandins) and anabolic and reparative

substances (growth factors, and inhibitors of catabolic cytokines), as well as inhibitors of degradative enzymes.<sup>4</sup> The balance of these three processes is key in maintaining a homeostatic joint environment. In OA, there exists an overproduction of destructive and pro-inflammatory mediators relative to the inhibitors. This “negative” overproduction results in a balance in favor of catabolism rather than anabolism, leading to the progressive lysis of articular cartilage.<sup>4</sup> Clinical signs of OA in the dog include lameness and joint pain. Affected dogs are reluctant to perform normal activities such as walking, climbing stairs, jumping, playing, and rising from a resting position.<sup>5</sup>

Non-steroidal anti-inflammatory drugs (NSAIDs) remain the current cornerstone of care, but often times dogs may not be able to tolerate this therapy, or it does not provide complete pain relief.<sup>6-10</sup> Dogs that become refractory to current prevailing medical therapies or cannot tolerate these medications have few viable options. Surgical intervention, such as total hip replacement, is a costly option with no guarantee of success. Many owners consider euthanasia when their dog’s pain cannot be controlled and/or when surgery is not a practical option.

The field of tissue engineering and regenerative medicine involves the study of the restoration of normal structure and function to damaged or missing tissues and organs, and shows promise for treating diseases such as OA.<sup>11-20, 34</sup> Tissue engineering therapies include cell-based approaches, scaffold-based approaches, bioactive molecular approaches, or combinations of the above. In contrast to drug therapy, regenerative medical therapy, such as using extracellular matrix (ECM) as a bioscaffold for tissue reconstruction, does not rely on a single target receptor or pathway for its action. Intact ECM contains a diversity of structural proteins and associated bioactive molecules, including cytokines and growth factors that act as potent modulators of cell behavior.<sup>21</sup> The growth factors contained in ECM include epidermal growth factor, transform-

ing growth factor beta, keratinocyte growth factor, hepatocyte growth factor, and platelet derived growth factor, among others.<sup>21</sup> Other components of ECM include collagens, proteoglycans, and glycoproteins.<sup>16</sup>

In contrast to using growth factors alone as a recently studied therapeutic approach, using ECM in its native state as a scaffold for tissue repair allows all the attendant growth factors as well as their inhibitors to be present in the locally relevant quantities that exist in nature, and in their native three-dimensional structure.<sup>21</sup> ECM exists in all tissues, yet can only be harvested for use as a scaffold from skin, urinary bladder, the submucosa of the small intestine, the pericardium, basement membrane, and a few other sources.<sup>16,21</sup> ECM scaffolds that are harvested in a manner that allow retention of the native structure, as opposed to chemical crosslinking, promote progenitor cell infiltration, rapid scaffold degradation, and deposition of host derived neomatrix that results in tissue remodeling with minimal scar tissue formation.<sup>21</sup> Porcine-derived urinary bladder extracellular matrix (UBM- ECM) represents a resorbable bioscaffold material that has been successfully used for the repair of musculotendinous structures,<sup>22-24</sup> lower urinary tract reconstruction,<sup>25-27</sup> dura mater replacement,<sup>28,29</sup> repair of full and partial thickness skin wounds,<sup>30</sup> and vascular and esophageal reconstruction.<sup>31-33</sup> The remodeling process in all of these applications has been remarkably similar.

ECM bioscaffolds typically degrade *in vivo* within 30-90 days and are replaced by site specific host cells that repopulate and/or augment host tissues that are missing, injured or otherwise deficient.<sup>16,21</sup> Initially, cellular infiltrate consisting of polymorphonuclear leukocytes and mononuclear cells occurs. By 72 hours, the cellular infiltrate is almost entirely mononuclear cells in appearance with early evidence for neovascularization. Between days 3 and 14, the number of mononuclear cells increases, vascularization increases, and there is a progressive degradation of the xenogeneic scaffold

with associated deposition of host derived neomatrix. Following day 14, the mononuclear cell infiltrate diminishes and there is the appearance of site specific parenchymal cells that orient along lines of stress. These parenchymal cells consist of fibroblasts, smooth muscle cells, skeletal muscle cells, and epithelial cells depending upon the site in which the scaffold has been placed.<sup>16,21</sup> Circulating, marrow derived progenitor cells participate in this remodeling process when ECM scaffolds are used.<sup>29</sup>

The acellular nature of the scaffold removes the major antigenic stimuli that would otherwise cause an adverse immune response.<sup>13</sup> The acellular matrix appears to provide signals to the host immune system that stimulate an adaptive or accommodative response that is ideal for both wound healing and three-dimensional growth of various cell types. The end result of this process is a site specific accumulation of organized and differentiated cells that perform very similar structural and functional purposes as the native tissue.<sup>11,20</sup> Xenogenic ECM is safe and effective in people with more than 100,000 human patients having now been implanted with a xenogenic ECM scaffold derived from the porcine small intestine submucosa for musculoskeletal conditions.<sup>21</sup> From small animals to the large animal patients, this innovative new tissue-engineered product offers veterinarians a valuable new treatment option. The objective of the present study is to evaluate the effectiveness of a particulate form of UBM-ECM, derived from porcine urinary bladder matrix (UBM), in decreasing lameness, pain, and disability in dogs with chronic osteoarthritis-associated joint pain.

## **MATERIALS AND METHODS**

### **Study Design**

Two companion animal veterinary practices in Michigan and Minnesota participated in this randomized, double-blind trial that included outpatient dogs with OA of the coxofemoral joint that was refractory to traditional therapy. Twenty dogs (10 females and 10 males), ages 3 years to 14 years, were recruited based on the diagnosis of

bilateral osteoarthritis of the hip joints with significant lameness that was non-responsive to standard medical therapy including non-steroidal anti-inflammatory drugs (NSAIDs). Radiographs, lameness examinations, and overall physical examinations were used to confirm bilateral hip OA. All dogs exhibited lameness that manifested as one or more of the following criteria: a reluctance to walk, climb stairs, jump, play, difficulty rising from a resting position, yelping in pain when touched, undergoing a personality change, and/or resistant to touch.

Before entering the study, all dogs underwent routine clinical chemistry and hematology evaluation to ensure overall health. Dogs were excluded from the study if they had any evidence of neoplasia or other diseases process that would interfere with interpretation of the results.

The 20 dogs were randomly assigned to two groups of 10. One group was treated with an intraarticular injection (hip joints) of a suspension of particulate UBM-ECM in saline. The second group, the control group, was injected in both hip joints with the saline carrier alone. All dogs were evaluated prior to entry into study and at several post-treatment time points for lameness, range of motion (ROM), and overall health by their veterinarian. The veterinarians and the pet owners were blinded to the animal's treatment or control group status. The blinded treatment was revealed only when the owner suggested withdrawing from the study due to perceived lack of response. Owners were responsible for maintaining a record of lameness and activity following the injections.

### **Study Blinding**

At the initiation of the study, each veterinarian received treatment packets labeled 1 to 10 that contained all study documentation, forms, and treatment material (5 packets contained the placebo treatment and 5 packets contained the UBM-ECM treatment.) for one patient. There was no difference in appearance of the treatment compared to the control doses. As an animal was enrolled

into the study, a patient treatment packet was opened and the animal was treated. The veterinarian and the client were initially blinded to the treatment the animal was receiving. Blindness was broken only when the animal receiving treatment showed no improvement and the client was unsatisfied, which occurred by day 28. The animals receiving the placebo treatment were then offered the opportunity to cross over to the treatment group (UBM-ECM) and continue evaluations in the study or withdraw from the study. Four patients initially receiving the placebo treatment did cross over and were entered into the treatment group (UBM-ECM).

### **Criteria for Entry into the Study**

All dogs must have been treated with standard of care pharmacologic methods and either been refractory to such therapy or became resistant to such therapy. The owners of each dog must have consented to the entry of their dog into the study and agreed to maintain a daily log of their pet's lameness and activity in the post-treatment period. The placement of the dogs into either the treatment or control group was random. All dogs in the study were removed entirely from any form of pharmacologic therapy at least one day prior to entry into the study.

### **Measured Endpoints**

Four endpoints were measured in this study: lameness score, range of motion score for extension, range of motion score for flexion, and activity level at the following time points: pre treatment, 1, 7, 28, 56, 84, 112, 140, and 168 days. Veterinarians and owners assessed the dog's lameness using a numerical rating scale of 1 to 10, where 1 is no lameness, 3 less than mild lameness upon rising and starting activity, 5 mild lameness when moving, 7 moderate lameness and dog does not want to play, and 10 severe lameness with dog exhibiting high pitched cry when touched or moved. Veterinarians measured ROM with a goniometer to establish each animal's baseline flexion and extension in each hip at each time point.

Goniometer measurements were taken with the dog in standing position. The hip joint flexion and extension angles were measured by placing the goniometer where the angles formed by the line joining the lateral femoral epicondyle of the femur and the greater trochanter and a line joining the tuber sacrale and ischiadicum. The operator flexed or extended the limbs until resistance was met due to pain. The reading was taken at that point of resistance. Owners scored their dog's activity on a scale from 1 to 10 (1=no activity to 10=very active). The same veterinarian examined each dog at each time point. Radiographs of each dog's hip joints were taken at pretreatment and at the final time point.

### **Test Article**

All UBM-ECM material for injection was manufactured and supplied by ACell®, Inc. (Columbia, MD) and is sold under the trade name ACell Vet Powder. Prior to packaging, the UBM-ECM was milled into a fine particulate. The resultant particles ranged in size from 50-250  $\mu$ m. The particulate ECM was then terminally sterilized by exposure to approximately 2.3 Mrad (23kGy) of e-beam irradiation.

### **Injection Procedure**

The suspension for injection was prepared using 100 mg of UBM-ECM particulate mixed with 1.5 ml sterile saline. A total volume of 1.5 ml (approximately 67 mg/ml) was drawn into a 3 cc syringe and set aside. Animals in the control group received only the saline injection (1.5 ml saline).

Each dog was anesthetized with tiletamine-zolazepam IV and maintained on isoflurane inhalant anesthesia following intubation. Each dog received bilateral injections. Dogs were placed in lateral recumbency while the coxofemoral joint area was aseptically prepped for the injection. A 20-gauge, 1 ½ inch needle for injection was inserted into the joint. Accurate placement of the needle was verified by the appearance of joint fluid. The syringe containing 1.5 ml total volume of UBM-ECM and saline

was attached to the needle and the suspension was injected into the joint. The same procedure was used for the control group, using saline only. Each dog was recovered from anesthesia and sent home 4 to 6 hours post-injection.

Based on the preclinical and clinical human literature indicating safety and efficacy for UBM-ECM, the clinical investigators approved the use of this test article in this clinical study.

### Statistical Analysis

The statistical significance of changes in clinical scores over time was determined by one-way repeated measures analysis of variance (ANOVA) on ranks. Comparisons of responses between groups were made by two-way ANOVA with treatment and day as grouping variables. Post hoc comparisons were made by the Tukey test. For visual comparisons (graphs) clinical data were expressed as % change from baseline in order to illustrate the magnitude of the changes over time and differences between treatment groups. All statistical computations were conducted using commercially available software (SigmaStat 3.5, Systat Software, Point Richmond, CA) at the nominal 0.05 level of significance.

### RESULTS

Nine of the ten dogs initially treated with UBM-ECM completed the study through day 168. In the 10 control dogs, owners suggested withdrawal due to perceived lack of response or unrelated health issues (1 case of cancer) at the post-treatment evaluations at day 28 in 6 dogs, day 56 in 3 dogs, and day 84 in 1 dog. Thus only 1 control dog completed the entire 168 days, showing no improvement, and 5 control dogs completed day 56 (see Table 1). Four of the control dogs were crossed over to the UBM-ECM group and subsequently treated with the UBM-ECM bioscaffold suspension, with the concurrence of the owners. Both the test article and the saline control were well tolerated by the dogs with no adverse reactions. No radiographic changes were noted from

pretreatment and post treatment time points.

### Veterinary and Owner Evaluations

Overall, all treated dogs improved compared to only 1 control dog. Four control dogs that originally demonstrated no improvement by Day 28 were crossed over and then treated with UBM-ECM, improved for the next 28 days. There were no significant differences at baseline between the test and control groups with regard to veterinarian or owner scores. Examination scores for activity, lameness, extension ROM, but not flexion ROM, improved significantly over time in the UBM-ECM treated group ( $p < 0.001$ ) after treatment, but not in the placebo group ( $p > 0.05$ ) (Table 1). Control animals that received saline only did not significantly improve over time in any category. The 4 control dogs that were crossed over and treated with UBM-ECM improved relative to the same parameters in the same dogs during the control period for the categories of activity ( $p=0.013$ ) and lameness ( $p=0.03$ ), and hip extension ( $p=0.055$ , ns), but not flexion ( $p \gg 0.05$ ) (Table 2). The improvement in clinical scores was statistically significantly greater ( $p < 0.05$ ) in the UBM-ECM treated group than in controls at all post treatment evaluation times through Day 56 for activity, lameness, and ROM for extension, but not for flexion (See Figures 1-3). The duration of effect in this study was at least 168 days (see Figure 4).

### Participant Survey

At the end of the study, the dog owners in the original treatment group (blinded) and the crossover group (unblinded) were asked to complete a participant's survey. In response to the question of how effective was the treatment in improving your dog's joint condition, of the 10 original treatment group owners (still blinded) and the 4 owners of dogs that crossed over (now unblinded), 1 participating in the UBM-ECM group, 3/1. Owners indicated the treatment was *effective* and 11/14 owners indicated the treatment was *very effective*. In the saline only control group, 1 out of 10 owners that finished the study indicated the treatment was effective

**Table 1:** UBM-ECM therapy improves activity, lameness, and range of motion scores in dogs with bilateral hip OA [mean ± sem (n)].

All dogs, all times

Day	Activity score, 1-10		Lameness/pain score, 1-10		Hip flexion, degrees		Hip extension, degrees	
	UBM-ECM	Control	UBM-ECM	Control	UBM-ECM	Control	UBM-ECM	Control
0	5.2 ± 0.5 (10)	3.9 ± 0.4 (10)	5.6 ± 0.5 (10)	5.6 ± 0.5 (10)	45.9 ± 3.7 (10)	39.3 ± 3.0 (10)	125.6 ± 2.6 (10)	130.8 ± 2.0 (10)
7	5.9 ± 0.4 (10)	4.0 ± 0.4 (10)	4.0 ± 0.5 (10)	5.2 ± 0.4 (10)	45.8 ± 2.9 (10)	38.4 ± 3.3 (10)	137.8 ± 1.7 (10)	129.3 ± 2.0 (10)
28	6.6 ± 0.5 (10)	4.1 ± 0.7 (10)	3.2 ± 0.5 (10)	5.1 ± 0.5 (10)	45.3 ± 2.9 (10)	38.8 ± 3.1 (10)	145.8 ± 2.8 (10)	136.5 ± 4.3 (10)
56	7.6 ± 0.5 (10)	4.7 ± 1.0 (5)	2.7 ± 0.4 (10)	5.5 ± 0.8 (5)	45.5 ± 2.9 (10)	37.2 ± 4.2 (5)	147.3 ± 2.7 (10)	138.8 ± 6.9 (5)
84	8.0 ± 0.4 (9)		2.6 ± 0.4 (9)		47.9 ± 3.0 (9)		150.4 ± 2.7 (9)	
112	8.2 ± 0.4 (6)		2.2 ± 0.3 (6)		45.0 ± 2.3 (6)		151.8 ± 2.8 (6)	
140	7.9 ± 0.5 (4)		2.5 ± 0.3 (4)		43.0 ± 2.8 (4)		151.5 ± 3.0 (4)	
168	7.7 ± 0.5 (9)		2.7 ± 0.3 (9)		41.8 ± 3.0 (9)		148.7 ± 3.3 (9)	
P value	p < 0.001*	ns**	p < 0.001*	ns**	not significant	ns**	p < 0.001***	ns**

\*Repeated measures analysis of variance (ANOVA) on ranks

\*\* ns = not significant (p > 0.05)

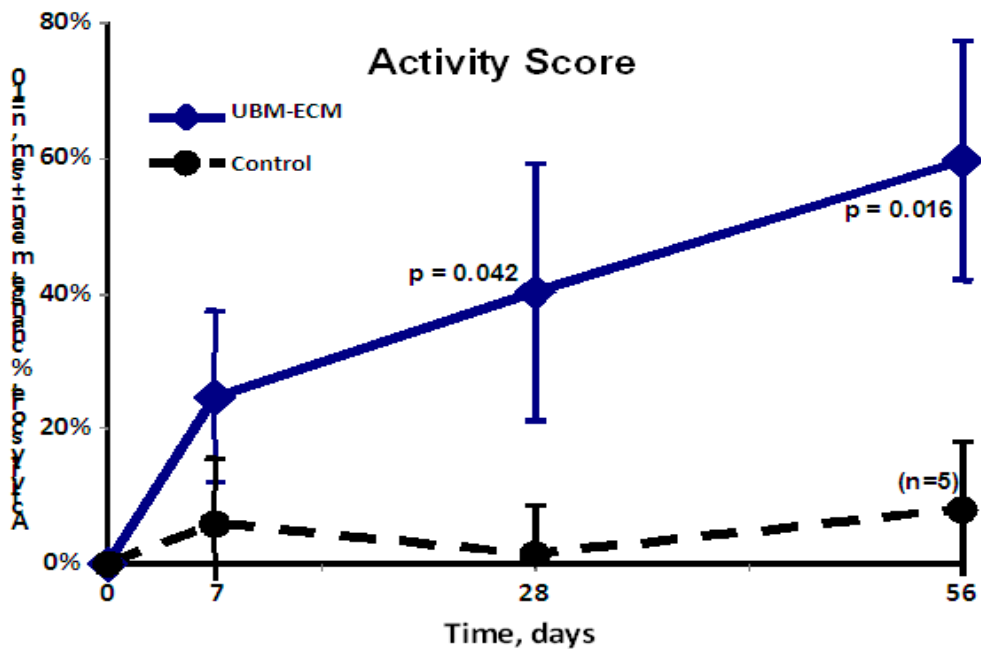
\*\*\*Repeated measures analysis of variance (ANOVA)

**Table 2:** UBM-ECM therapy improves activity lameness, and range of motion scores in original control dogs crossed over and treated (mean + sem, n=4)  
Crossover dogs, n=4

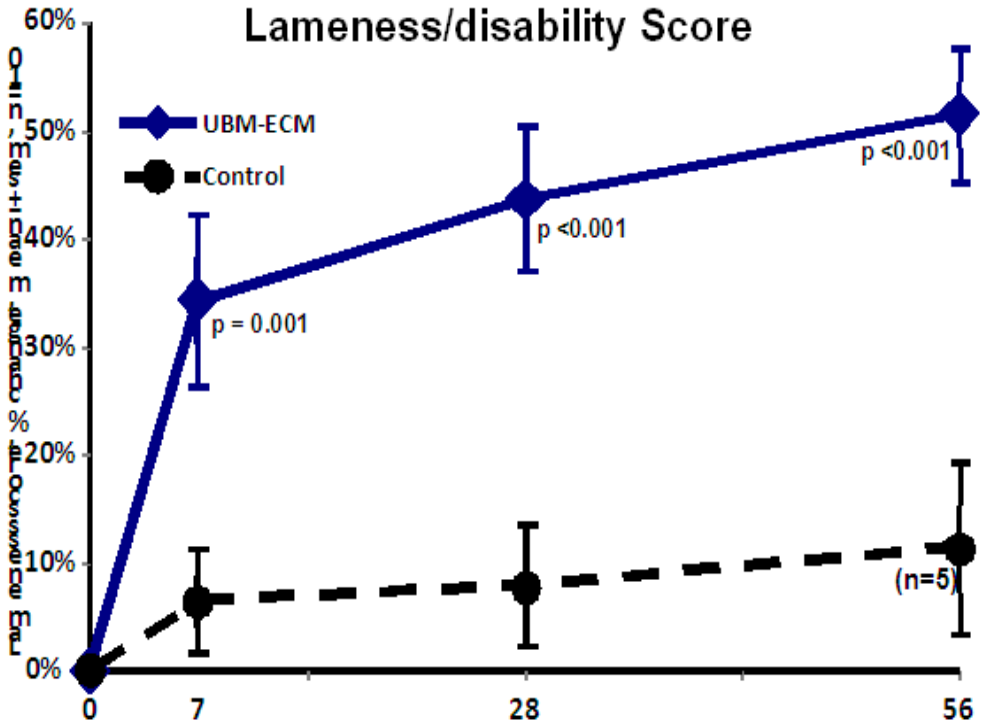
Day	Activity score, 1-10		Lameness/pain score, 1-10		Hip flexion, degrees		Hip extension, degrees	
	UBM-ECM	Control	UBM-ECM	Control	UBM-ECM	Control	UBM-ECM	Control
0	3.5 ± 0.5	3.5 ± 0.5	4.8 ± 0.3	4.8 ± 0.3	42.5 ± 4.3	42.5 ± 4.3	129.8 ± 1.4	129.8 ± 1.4
7	5.3 ± 0.1	3.3 ± 0.629	3.5 ± 0.9	4.8 ± 0.3	44.1 ± 3.8	40.3 ± 5.9	137.0 ± 4.8	128.5 ± 1.5
28	6.8 ± 0.5	3.3 ± 0.629	2.3 ± 1.3	4.8 ± 0.3	43.5 ± 2.5	41.3 ± 5.1	154.4 ± 7.3	132.4 ± 0.7
Difference*	p=0.013		p=0.033		not significant		p=0.055(ns)	

\*Two-way repeated measures analysis of variance (ANOVA)

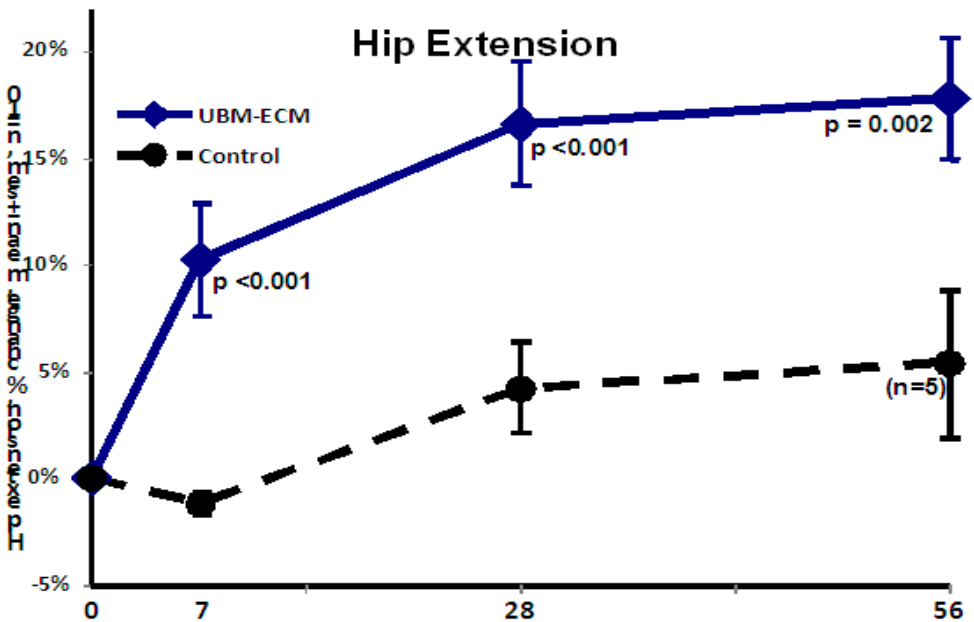
**Figure 1:** Percent improvement in activity in UBM-ECM- treated and control dogs. Treated dogs significantly improved relative to control dogs.



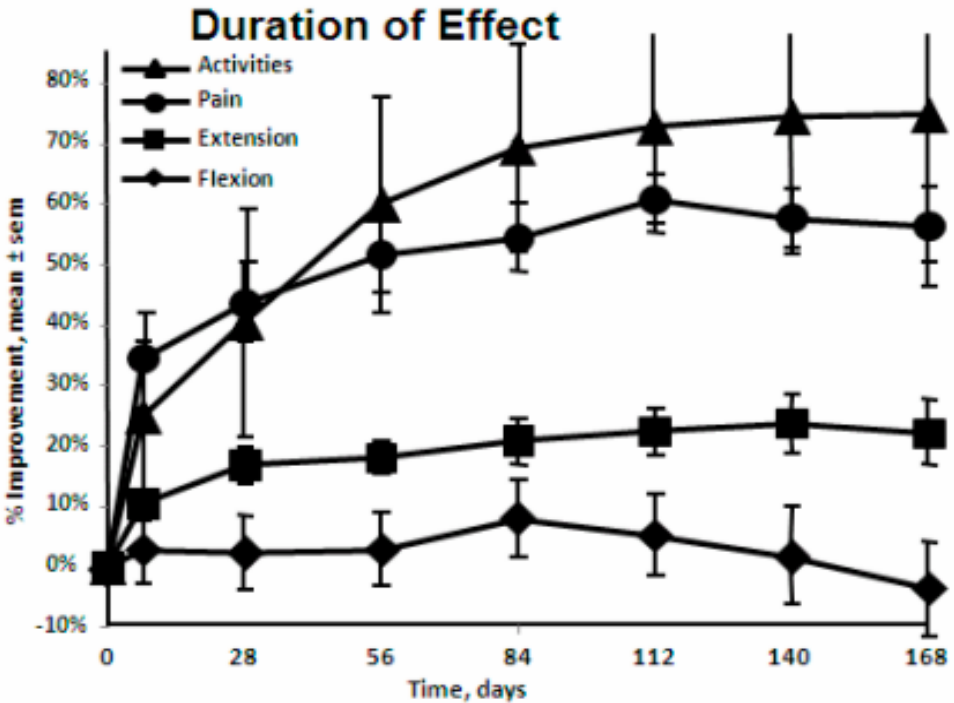
**Figure 2:** Percent improvement in lameness in UBM-ECM- treated and control dogs. Treated dogs significantly improved relative to control dogs.



**Figure 3:** Percent improvement in range of motion (extension) in UBM-ECM- treated and control dogs. Treated dogs significantly improved relative to control dogs.



**Figure 4:** Percent improvement and duration of effect in activity, pain (lameness), range of motion-extension, and range of motion-flexion in UBM-ECM- treated dogs. Treated dogs improved in all categories except flexion with duration of effect of at least 168 days. Control dogs remained without significant improvement over time.



and no owners indicated the treatment was very effective.

In response to the question of did the effect of the UBM-ECM product on your dog’s joint condition improve its overall quality of life as assessed by the dog’s activity, mobility, and attitude, 14 out of 14 owners participating in the UBM-ECM group indicated the treatment did improve their animal’s quality of life.

**DISCUSSION**

Many dogs continue to suffer with chronic pain associated with OA as they either cannot tolerate traditional NSAID therapy or they become refractory to therapy. Regenerative medicine options, such as UBM, offer an additional treatment regime that may be effective for OA. The present study evaluated the efficacy of an UBM-ECM Bioscaffold-based approach for the treatment of chronic refractory OA in the hip

joint in the dog. Results of this double-blind, placebo-controlled study demonstrate that UBM-ECM therapy resulted in improved activity levels, lameness, and range of motion in dogs over time and relative to control animals.

The current study design employs a subjective numerical rating scale to assess degree of lameness by veterinarians. Quinn and colleagues recently demonstrated that subjective scoring scales are not a replacement for force plate analysis.<sup>34</sup> However, subjective scoring systems are useful in clinical settings such as the multicenter setting of this trial, where a forceplate device is impractical. The blinded nature of the study during the first 28 days helps to ensure that bias is negligible.

Although the design of this study does not elucidate the mechanism(s) by which UBM-ECM exerts its effects, it was presumed that it acts as a bioscaffold, encourag-



ing appropriate regenerative cells to colonize or that the product provided necessary cytokines that may have decreased inflammation. As with many emerging regenerative medicine therapeutics, the molecular mechanisms underlying the clinical efficacy demonstrated in this and other studies have yet to be determined. However, in theory, the scaffold may provide a means for new collagen formation and that the growth factors present in the bioscaffold contribute to both the normal articular milieu and to new cartilage formation. For example, preclinical studies using a dog model of medial meniscal resection demonstrated a rapid and complete replacement of the ECM bioscaffold by virtually normal meniscal cartilage within 3 to 6 weeks and so demonstrates the principal of site-specific tissue reconstruction with an ECM bioscaffold.<sup>35</sup>

However, in the current study, treated dogs demonstrated improvement as early as 7 days, a time point that would appear too early for new cartilage formation. Therefore, it seems more likely that, as with mesenchymal stem cells, the cytokines contained in the ECM may have an anti-inflammatory effect that may also be aiding in decreasing lameness in dogs with OA of the hip joint. Additional mechanistic studies are necessary to more fully understand the reason for the clinical efficacy seen in this study.

A few limitations of the study are noted. Although sample size was small, significance was reached in treated dogs by day 28 indicating that the positive effects were unlikely due to chance. Also, while control dogs in the blinded portion of the study participated for only 56 days out of the 168 days, when 4 of these dogs were crossed over and were treated, they improved similarly to the treated dogs, suggesting that their improvement was likely due to the UBM-ECM. Therefore, despite the small sample size, there is still good indication that UBM-ECM is responsible for the clinical improvement in these dogs. Histologic evaluation of the remodeling joint would add insight into the mechanism of UBM-ECM. However, studying a naturally

occurring condition such as lameness from chronic OA in client-owned pets often precludes the type of comprehensive diagnostic testing and follow-up that would be desirable in a controlled study using experimental animals. Despite the limitations, the results support the hypothesis that UBM-ECM, a naturally derived, non-crosslinked bioscaffold, improves clinical signs of chronic OA in the hip joints of dogs

The advantages of using UBM-ECM for dogs with OA of the hips include decreased lameness, demonstrated long-term duration of effect, and the outpatient nature of the procedure. Decreasing lameness provides a better quality of life for the dog. Additional studies are needed to determine if the treatment effects remain beyond 168 days. The results of the present study suggest that at least four to five months is a reasonable expectation for duration of effect. Larger study groups and greater experience with dogs affected by joint disease will be required to address the full potential of this treatment option.

## CONCLUSION

The current study demonstrates that dogs with chronic OA of the hip joints that are treated by intraarticular injection with the xenogeneic urinary bladder extracellular matrix bioscaffold have significant improvement in activity levels, lameness, and range of motion with at least a 5-month duration of effect. This regenerative medicine therapeutic option provides a new tool for veterinarians in treating OA in dogs.

## ACKNOWLEDGEMENTS

We the authors gratefully thank Dr. Dan Gingerich for his statistical analysis (Turtle Creek Biomedical Consulting in Lebanon, Ohio) and Dr. Linda Black for her assistance with editing the manuscript (Black Horse Enterprises, Inc., Scientific & Biomedical Consulting).

## REFERENCES

1. Hedhammar A, Olsson SE, Andersson SA, et al. Canine hip dysplasia: study of heritability in 401 litters of German Shepherd dogs. *J Am Vet Med Assoc* 174:1012-1016, 1979.

2. Johnson JA, Austin C, Breur GJ. Incidence of canine appendicular musculoskeletal disorders in 16 veterinary teaching hospitals from 1980 to 1989. *Veterinary Comparative Orthopedics and Traumatology* 7:56-69, 1994.
3. Moore GE, Burkman KD, Carter MN, et al. Causes of death or reasons for euthanasia in military working dogs: 927 cases (1993-1996). *J Am Vet Med Assoc* 219:209-214, 2001.
4. Mortellaro CM. Pathophysiology of osteoarthritis. *Vet Res Comm* 27Supp:75-78, 2003.
5. Bennet D, May C. Joint diseases of dogs and cats. In Ettinger SJ (ed) *Textbook of Veterinary Internal Medicine* (4th Edn.) W.B. Saunders and Co:1995:2053-2059.
6. Lascelles BD, Main DC. Surgical trauma and chronically painful conditions--within our comfort level but beyond theirs? *J Am Vet Med Assoc* 221:215-222, 2002.
7. Budsberg SC, Johnston SA, Schwarz PD, et al. Efficacy of etodolac for treatment of osteoarthritis of the hip joints in dogs. *JAVMA* 214:206-210, 1999.
8. Holtsinger RH, Parker RB, Beale BS, et al. The therapeutic efficacy of carprofen (Rimadyl-V) in 209 clinical cases of canine degenerative joint disease. *Veterinary and Comparative Orthopedics and Traumatology* 5:140-144, 1992.
9. Vasseur P, Johnson A, Budsberg S, et al. Randomized, controlled trial of the efficacy of carprofen, a nonsteroidal anti-inflammatory drug, in the treatment of osteoarthritis in dogs. *JAVMA* 206(6):807-811, 1995.
10. Johnson SA, Budsberg SC. Nonsteroidal anti-inflammatory drugs and corticosteroids for the management of canine osteoarthritis. *Vet Clin North Am Small Anim Pract* 27:841-862, 1997.
11. Musahl V, Abramowitch SD, Gilbert TW, et al. The use of porcine small intestinal submucosa to enhance the healing of the medial collateral ligament--a functional tissue engineering study in rabbits. *J Orthop Res* 22(1): p. 214-120, 2004.
12. Gilbert T, Nieponice A, Spievack AR, et al. Repair of the Thoracic Wall with an Extracellular Matrix Scaffold in a Canine Model. *J Surg. Res* 147, 61-67, 2008.
13. Gilbert T W, Gilbert S, Madden M, et al. Morphologic Assessment of Extracellular Matrix Scaffold for Patch Tracheoplasty in a Canine Model. *Ann. Thorac. Surg* 86:967-74, 2008.
14. Wood JD, Simmons-Byrd A, Spievack AR, et al. Use of a particulate extracellular matrix bioscaffold for treatment of acquired urinary incontinence in dogs. *JAVMA* 226(7):1095-7, 2005.
15. Gilbert TW, Stolz DB, Biancianiello F, et al. Production and characterization of ECM powder: implications for tissue engineering applications. *Biomaterials*. 26(12):1431-1435, 2005
16. Badylak SF. Extracellular Matrix as a Scaffold for Tissue Engineering in Veterinary Medicine: Applications to Soft Tissue Healing. *Clinical Techniques in Equine Practice*, 3:173-181, 2004.
17. Badylak SF, Vorp DA, Spievack AS, et al. Esophageal Reconstruction with ECM and Muscle Tissue in a Dog Model. *J Surg Res* 128:87-97, 2005.
18. Nieponice A, Gilbert TW, Badylak SF. Reinforcement of Esophageal Anastomoses With an Extracellular Matrix Scaffold in a Canine Model. *Ann. Thorac Surg* 82:2050-8, 2006.
19. Stone RL, Sweeney JC, Levine G, et al. Utilization of Reconstructive Surgery, Extracellular Matrix, and Light Emitting Diode Technology to Return form and Function to a Young Dolphin's Dorsal Fin. (Abstract)
20. Smith H. A-Cell Therapy Offers Renewed Hope For Horses Incurring Tendon And Ligament Injuries. *The Chronicle of the Horse*, 2005, June 24; 134-137.
21. Badylak SF. The extracellular matrix as a scaffold for tissue reconstruction. *Semin Cell Dev Bio* 13(5):377-383, 2002.
22. Kropp BP, Sawyer BD, Shannon He, et al. Characterization of small intestinal submucosa-regenerated canine detrusor: assessment of reinnervation, in vitro compliance and contractility. *J Urol* 156:599-607, 1996.
23. Kropp BP, Rippey MK, Badylak SF, et al. Regenerative urinary bladder augmentation using small intestinal submucosa: urodynamic and histopathologic assessment in long term canine bladder augmentations. *J Urol* 155:2098-2104, 1996.
24. Cobb MA, Badylak SF, Janas W, et al. Histology after dural grafting with small intestinal submucosa. *Surg Neurol* 46:389-394, 1996.
25. Cobb MA, Badylak SF, Janas W, et al. Porcine small intestinal submucosa as a dural substitute. *Surg Neurol* 51(1):99-104, 1999.
26. Sandusky GE, Lantz GC, Badylak SF. Healing comparison of small intestine submucosa and ePTFE grafts in the canine carotid artery. *J Surg Res* 58:415-420, 1995.
27. Prevel CD, Eppley BL, McCarty M, et al. Experimental evaluation of small intestine submucosa as a microvascular graft material. *J Microsurg* 15:588-591, 1994.
28. Badylak SF, Lantz G, Coffey A, et al. Small intestinal submucosa as a large diameter vascular graft in the dog. *J Surg Res* 47:74-80, 1989. Badylak SF, Park K, Peppas N, et al. Marrow-derived cells populate scaffolds composed of xenogeneic extracellular matrix. *Exp Hematol* 29:1310-1318, 2001.
30. Badylak SF, Meurling S, Chen M, et al. Resorbable bioscaffolds for esophageal repair in a dog model. *J Pediatr Surg* 35:1097-1103, 2000.
31. Prevel CD, Eppley BL, Summerlin DJ, et al. Small intestinal submucosa: Utilization as a wound dressing in full-thickness rodent wounds. *Ann Plast Surg* 35:381-388, 1995.
32. Hodde JP, Badylak SF, Shelbourne KD. The effect of range of motion on remodeling of small intestinal submucosa when used as an Achilles' tendon repair material in the rabbit. *Tissue Eng* 3:27-37, 1997.
33. Vaught JD, Kropp BP, Sawyer BD, et al. Detrusor regeneration in the rat using porcine small intestinal submucosal grafts: functional innervations and receptor expression. *J Urol* 155:374-378, 1996.
34. Quinn M, Keuler N, Lu Y, et al. Evaluation of agreement between numerical rating scales, visual analogue scoring scales, and force plate gait analysis in dogs. *Vet Surg* 36:360-367, 2007
35. Cook JL, Tomlinson JL, Kreeger JM, et al. Induction of meniscal regeneration in dogs using a novel biomaterial. *AJ Sports Med* 27:658-665, 1999.