

# Porcine urinary bladder extracellular matrix grafts (ACell Vet<sup>®</sup> Corneal Discs) for keratomalacia in 17 equids (2012–2013)

Laura A. Mancuso,\* Mary Lassaline† and Nicole M. Scherrer\*

\*New Bolton Center, School of Veterinary Medicine, University of Pennsylvania, 382 W. Street Road, Kennett Square, PA, 19348, USA; and †Department of Surgical and Radiological Sciences, School of Veterinary Medicine, University of California-Davis, One Shields Avenue, Davis, CA, 95616, USA

Address communications to:

M. Lassaline

Tel.: (530) 752-0920

Fax: (530) 752-0454

e-mail: lasutter@ucdavis.edu

## Abstract

**Objective** To describe the clinical course, outcomes, and complications associated with use of commercially available porcine urinary bladder extracellular matrix (ECM) grafts (ACell Vet<sup>®</sup> Corneal Discs) in equid patients with keratomalacia, and to evaluate the efficacy of ECM grafts as a viable alternative to other biomaterials for corneal grafting in equid patients.

**Animals** Sixteen horses and one donkey (17 eyes) with unilateral keratomalacia severe enough to warrant surgical repair between August 2012 and September 2013.

**Procedure** Retrospective medical record review to identify equid patients meeting inclusion criteria of (i) diagnosis with keratomalacia severe enough to warrant surgical repair and (ii) surgical repair with an extracellular matrix graft.

**Results** Eleven geldings, four mares, and two colts met inclusion criteria. Patients averaged 9 years of age. Twelve of 17 eyes (71%) were considered infected based on either corneal cytology (10/17, or 59%) or corneal culture (12/17, or 71%) positive for bacteria (8/17, or 47%) or fungi (9/17, or 53%). At the time topical medications were discontinued, 16 eyes (94%) were visual. One operated eye ruptured 5 days postoperatively and was enucleated. Keratouveitis developed in 14/14 eyes that underwent regular examinations approximately 2 weeks postoperatively which responded to systemic nonsteroidal anti-inflammatory drug therapy.

**Conclusions** Extracellular matrix grafts may be a viable alternative to other biomaterials for corneal grafting in equids. Advantages include commercial availability and shelf storage.

**Key Words:** equine, extracellular matrix, graft, keratitis, ulcer

## INTRODUCTION

Corneal grafting is a surgical procedure utilizing biomaterials such as donor tissue or acellular collagen derivatives to serve one of a number of functions, including to provide tectonic support to replace missing tissue; when corneal disease does not resolve or progresses in the face of aggressive and appropriate medical management; to reduce ocular pain; and to improve optical clarity. Clinically, the recommendation to pursue surgical intervention depends upon numerous factors including the type and duration of prior medical therapy and the candidacy of the patient for general anesthesia, although any corneal defect subjectively judged deep enough to threaten corneal perforation typically warrants surgical repair.<sup>1</sup>

Numerous biomaterials are described for use in medical and veterinary corneal grafting, including but not limited

to xenogeneic,<sup>2</sup> homologous,<sup>3–5</sup> autogenous<sup>5</sup> cornea, conjunctiva,<sup>1</sup> amniotic membrane,<sup>6–8</sup> and porcine small intestinal submucosa (SIS).<sup>9–11</sup> The ideal biomaterial for corneal grafting should provide optical clarity and possess resistance to endogenous corneal proteases, mimic normal passage of solutes, and promote epithelial growth.<sup>10</sup> Although an individual case report describing application of porcine urinary bladder ECM (ACell Vet<sup>®</sup> Corneal Discs, Columbia, MD, USA), in an attempt to repair bullous keratopathy associated with trauma in a great horned owl does appear in the literature,<sup>12</sup> its clinical application in the surgical treatment of keratomalacia in equids has not yet been investigated.

Biomaterial grafts in surgical repair of corneal disease were first documented in the 1700s, utilizing transplanted corneal tissue from cadavers or enucleated donors,<sup>13</sup> with a successful penetrating homograft anecdotally reported in

a veterinary patient in 1837.<sup>14</sup> Cross-species donation and limited asepsis led to profound corneal opacification or globe loss in most of these early grafting attempts.<sup>15</sup> The advent of microsurgical tools, graft preservation media, and infection control produced the first successful human corneal homograft in 1905, which retained long-term transparency and restored marginal vision.<sup>3</sup> Fresh or frozen corneal homografts and autografts are all documented with success in veterinary literature.<sup>4,5,16–18</sup> More recent advancements in penetrating and lamellar keratoplasty are vast and have contributed immeasurably to restore vision in equine corneal disease.<sup>19</sup>

Despite profound improvements in surgical and medical management, fibrotic scarring at the graft site persists as the major impediment preventing postoperative return to function. Some loss of optical clarity is expected with all available biomaterials, with minimal scarring occurring only when the cornea heals with topical medications alone, without a graft.<sup>10</sup> The potential for long-term transparency is an important property to consider during evaluation of biomaterials such as commercially available, acellular collagen products such as porcine small intestinal submucosa (SIS) and urinary bladder ECM (ACell<sup>®</sup>), particularly in comparison with their more extensively documented alternative, the conjunctival autograft.

Conjunctival pedicles remain an effective biomaterial for surgical repair of the cornea in veterinary species, achieving both functional and anatomical success.<sup>19–21</sup> Conjunctiva lends excellent structural integrity to a compromised cornea and provides blood vessels to an otherwise avascular region, delivering nutrients for epithelial proliferation, protective leukocytes, antibodies, anticollagenase compounds, and systemic antimicrobials.<sup>1,21</sup> However, conjunctival flaps are opaque, produce unpredictable and potentially extensive corneal fibrosis, and may severely impair optical clarity when lesions are large or graft resection impractical.<sup>11,22</sup>

Amniotic membrane transplants are used in similar fashion to conjunctival pedicles, but they may provide increased tectonic support as well as improved postoperative optical clarity, rapid epithelial migration across a bare basement membrane, and endogenous anti-angiogenic, anti-protease, anti-inflammatory, and antifibrotic cytokines and growth factors that prevent corneal melting and scarring through various molecular mechanisms.<sup>7,8,23</sup> However, tissue harvest can result in time-consuming challenges, and amnion is not currently commercially available.

Porcine small intestinal submucosa is another biomaterial that has been used in corneal grafting in veterinary patients<sup>9–11</sup> and differs from cornea, conjunctiva, and amnion in being both commercially available and acellular. Acellularity should be associated with less of an immune response and therefore limited graft rejection. Porcine small intestinal submucosa acts as porous scaffolding and thus incorporates into new host tissue rather than

destroying normal structure with a scar, freely diffusing solutes and topical medications, while supplying endogenous growth factors, such as FGF-2 and TGF- $\beta$ , to encourage cellular and vascular ingrowth.<sup>11,23</sup> Porcine small intestinal submucosa has demonstrated efficacy in corneal repair comparable to more traditional conjunctival autografts, with potential to reduce postoperative scarring.

Extracellular matrix products such as ACell<sup>®</sup> grafts are similar to porcine small intestinal submucosa in that they contain no living cells, but rather growth factor and collagen components of the porcine urinary bladder's extracellular matrix. ACell<sup>®</sup> powders, lyophilized sheets, and corneal discs are advertised as scaffolding that first promotes cellular proliferation and regeneration, then degrades as local tissues replace the graft, such that no foreign material remains, potentially associated with a reduction in fibrotic scarring and pain.

Investigation into the use of ACell<sup>®</sup> corneal discs in domestic veterinary species independent of the manufacturer's claims has not yet been published. The purpose of this retrospective study was to describe the clinical course, outcomes, and complications associated with use of commercially available porcine urinary bladder extracellular matrix (ECM) grafts (ACell Vet<sup>®</sup> Corneal Discs) in horses with keratomalacia and therefore to evaluate the efficacy of ECM grafts as a viable alternative to other biomaterials for corneal grafting in equid patients.

## METHOD

### *Case selection*

Equid patients included in this study met two inclusion criteria: (1) presentation to the Ophthalmology Service at the University of Pennsylvania's New Bolton Center between May 2012 and April 2013, and (2) diagnosis by a board-certified veterinary ophthalmologist (ML) with unilateral, partial-thickness keratomalacia severe enough to warrant surgical repair. Diagnosis and surgical recommendations were based upon complete ophthalmic examination, positive corneal fluorescein uptake, ulcer diameter as measured by a ruler and depth as estimated on slit-lamp examination, cytology, and culture growth. All patients underwent a variable period of topical and systemic medical management prior to surgery and were deemed surgical candidates if corneal lesions were of a depth sufficient to threaten globe rupture, or if they were historically refractory to medical management.

Medical records of included patients were reviewed to identify signalment, history of the corneal complaint and clinical course of corneal disease, surgical reports from each individual's ACell<sup>®</sup> corneal disc placement, postoperative complications, and eventual outcome with respect to the retention of functional vision from that globe. Follow-up regarding ocular comfort and corneal clarity was via in-patient observation at New Bolton Center, recheck appointments, and communication with owners and

attending veterinarians over approximately 5–8 weeks postoperatively.

End point outcomes were evaluated at removal of the subpalpebral lavage (SPL) catheter and termination of topical medications. Favorable surgical outcome was defined as both a visual and tectonically intact globe, permitting some development of pain and corneal scarring. Unfavorable surgical outcome was defined as loss of functional vision from that eye for any reason, with or without loss of the globe.

### *Patients*

All patients underwent complete ophthalmic examination by a single board-certified veterinary ophthalmologist (ML), with corneal fluorescein staining, cytology, and culture performed. Cultures were evaluated for both bacterial and fungal growth, and bacterial isolates were subjected to antimicrobial susceptibility. The adnexa, anterior, and posterior ocular segments of both eyes were examined with a Finoff transilluminator (Heine USA, Dover, NH, USA), slit-lamp biomicroscope (SL 15; Kowa, Tokyo, Japan), and direct and indirect ophthalmoscopes (Heine USA).

### *Surgical technique*

All patients included in this study underwent general anesthesia in lateral recumbency for keratectomy and placement of an ACell<sup>®</sup> corneal disc graft. Affected eyes were routinely prepared for corneal surgery. All patients received intra-operative intravenous fluid therapy and systemic broad-spectrum antibiotics. ACell<sup>®</sup> manufacturer's instructions to withhold topical medications for 48 h prior to graft placement were ignored in every case.

All surgeries were performed using an operating microscope. A keratectomy was performed using a 6400 Beaver blade or Westcott tenotomy scissors to excise necrotic or infected cornea. The resulting corneal defect was measured using Jameson calipers. The ACell<sup>®</sup> corneal disc was trimmed with margins approximately 1 mm larger than the keratectomy field, laid outside-up as per manufacturer's instructions, wetted with sterile saline, and sutured into surrounding healthy anterior cornea with simple interrupted 8-0 braided polyglactin 910 about 2 mm apart. Figure 2 demonstrates a secure, intra-operative graft.

### *Postoperative care*

A subpalpebral lavage catheter was placed either prior to or just following surgery to facilitate delivery of topical medications. To protect the graft site during healing, the eyelids were closed by complete temporary tarsorrhaphy with three interrupted 5-0 monofilament polyglecaprone 25 horizontal mattress sutures through rubber stents. The temporary tarsorrhaphy was left in place for 1–3 weeks of postoperative medical management via the subpalpebral lavage catheter. All patients were treated with a systemic nonsteroidal anti-inflammatory, either flunixin meglumine or firocoxib, with dose decreasing based on clinical signs.

During each recheck examination, a complete ocular examination of the operated eye was performed by a boarded ophthalmologist, and judgments of quality of vision, degree of comfort, extent of corneal vascularization, degree of corneal fibrosis, and proportion of corneal clarity were made. The end point of medical therapy was classified as the time at which all topical medications were discontinued, and the subpalpebral lavage catheter was removed. End point outcomes were evaluated when the subpalpebral lavage catheter was removed. Criteria for discontinuing medical therapy included negative fluorescein stain, the absence of stromal infiltrate on slit-lamp examination, and acceptable ocular comfort.

Discontinuation of medical therapy and removal of the subpalpebral lavage catheter was used as an end point metric rather than length of hospitalization. Length of hospitalization was not necessarily correlated with disease progression or resolution in this patient population, as typically in this population some patients are discharged to local layup facilities for continued medical care within a day or two following surgery, returning for rechecks or being examined at the layup facility by a boarded veterinary ophthalmologist, whereas other patients remained in hospital for the duration of medical therapy due to the distance travelled between their home barn and the hospital and the absence of a boarded veterinary ophthalmologist near their home barn. That is, in this latter group, continued hospitalization would not imply persistently severe disease requiring hospitalization, but rather simply that these patients remained hospitalized until the end of medical therapy to stay under the direct care of a boarded veterinary ophthalmologist.

### *Statistical analysis*

Descriptive statistics were computed for all recorded variables. Frequencies were calculated for the categorical variables patient sex (mare, gelding, or colt), breed, presence of infectious organisms on corneal cytology (none, bacterial, or fungal), growth of infectious organisms on corneal culture (none, bacterial, or fungal), and visual outcome (visual or nonvisual) using SAS FREQ (UNIVARIATE procedure, SAS, version 9.3; SAS Institute Inc., Cary, NC). Means and standard deviations were computed for the interval-scaled variables age at diagnosis (in years), estimated size of corneal lesion (in mm), and estimated depth of corneal lesion (in percent) using SAS UNIVARIATE (FREQ procedure, SAS, version 9.3; SAS Institute Inc.). Because data were descriptive and no group comparisons were made, no inferential statistics were performed.

## RESULTS

### *Signalment*

Sixteen horses and one donkey (17 eyes) were diagnosed at New Bolton Center, between May 2012 and April 2013, with unilateral, partial-thickness keratomalacia

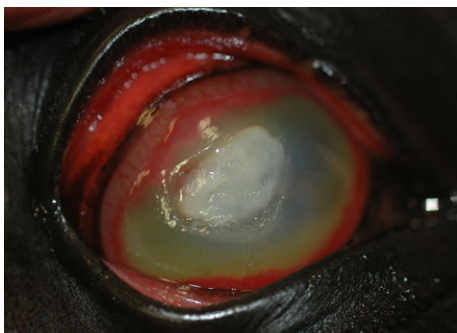severe enough to warrant surgical repair, and were included in this study. Figures 1 and 4 depict the clinical presentations of two cases with characteristic ‘catastrophic corneas’ at high risk for progression and perforation. Surgical recommendations and thus subsequent inclusion in the retrospective study were based upon examination by a board-certified veterinary ophthalmologist (ML).

Eleven geldings, four mares, and two colts met inclusion criteria. Patients averaged 9 years of age, SD 6 years, ranging in age from 4 months to 18 years. Breeds represented were Thoroughbred (7/17, or 41%), Standardbred (3/17, or 18%), Warmblood (2/17, or 12%), and one each (6%) of Quarter Horse, Friesian, Welsh Cob, Miniature Horse, and Miniature Donkey. No breed or sex was over-represented in the patient sample relative to general hospital population.

### History

Duration of ophthalmic clinical signs prior to presentation averaged 11 days, SD 8 days, ranging from 1 to 28 days. Two eyes had previously been treated with topical steroids. One eye had suffered traumatic corneal laceration from a wooden foreign object. All affected eyes were visual on presentation with a positive pupillary light reflex from the affected to the unaffected eye. Corneal edema limited examination of intraocular structures in most cases. Corneal ulcers in affected eyes averaged 12 mm in diameter, with a SD of 6 mm, ranging from 2 to 25 mm in diameter. Ulcers were subjectively reported to range from 50% to 90% in depth.

Surgery was performed on four patients the day of admission and initial examination based on severity of keratomalacia and perceived depth of the corneal lesion, and was performed the day following admission in 12 patients to allow overnight stabilization of the patient and the cor-



**Figure 1.** Pre-operative catastrophic cornea in 13-year-old Standardbred stallion, from mixed bacterial–fungal infectious keratitis (*Streptococcus* and *Aspergillus*) refractory to medical treatment. The horizontally oval axial fungal plaque is surrounded by a deep stromal furrow that threatened globe integrity. Corneal vascularization has advanced almost to the furrow superiorly. The cornea is characterized by a diffuse stromal infiltrate and severe edema precluding view of structures posterior to the cornea but for a faint outline of a miotic pupil and hypopyon inferiorly and nasally.

nea. In these 12 patients, a subpalpebral lavage catheter was placed, and aggressive medical therapy instituted at admission. One patient, a 12-year-old Thoroughbred gelding, had been admitted to the hospital with a complaint of eosinophilic keratitis which was complicated by fungal keratitis, and was treated surgically on the fifth day of hospitalization when the condition of the cornea acutely worsened from the prior day. All 17 patients were subjected to similar pre-operative medical management, including the following medications: systemic nonsteroidal anti-inflammatory (flunixin or firocoxib), topical antimicrobial (ofloxacin, and cefazolin if bacterial cocci were noted on corneal cytology), systemic antimicrobial (one horse, doxycycline), topical antifungal (voriconazole), topical anticollagenase (autologous serum), and topical mydriatic (atropine). Additionally, one patient was treated with systemic doxycycline as both antimicrobial and anticollagenase, and one patient received systemic cetirizine to address historical eosinophilic keratitis.

### Corneal infection

Ten of 17 eyes (59%) had cytology suggestive of corneal infection, with bacteria (2), fungi (6), or both (2) observed. Cytology revealed incidental epithelial cells in 17 horses (100%) and neutrophils in 10 horses (59%), even in the absence of infectious organisms. All 10 eyes with cytologic evidence of infection were also positive on culture, with two additional eyes that did not have cytologic evidence of infection positive on bacterial culture. Twelve of 17 eyes (71%) were considered infected based on corneal culture positive for bacteria alone (4/17, or 24%), fungi alone (4/17, or 24%), or mixed infection with both bacteria and fungi (4/17, or 24%). Regarding the correlation between cytology and culture, both tests revealed the same type of infectious organism in six of 10 eyes for which cytology and culture were both positive; one eye had cytology positive for both bacteria and fungi but had culture positive only for bacteria; one eye had cytology positive only for bacteria but was culture positive for both bacteria and fungi; and two eyes had cytology positive only for fungi but were culture positive for both bacteria and fungi.

Bacterial corneal infection was diagnosed from culture growth of *Streptococcus zooepidemicus* in 4/17 horses (24%), and from growth in 1/17 horses in each of *Pseudomonas aeruginosa*, *Streptococcus warneri*, *Staphylococcus xylosum*, and an *Enterococcus* sp. Fungal corneal infection was diagnosed from culture growth of *Aspergillus* species in 8/17 horses (47%); no other fungal pathogen was isolated. Four horses with cultures positive for *Aspergillus* were also positive for a bacterial organism.

### Surgery

All patients underwent general anesthesia for ulcer debridement by keratectomy and placement of an ACell® corneal disc graft as described earlier. Two layers of



ACell<sup>®</sup> graft were placed over the keratectomy site in two cases with aggressive fungal keratitis that was associated with profound corneal malacia. The first case was a 7-year-old Friesian gelding who also presented with advanced, preexisting renal disease that precluded use of NSAIDs. The second case receiving a double-layer ACell<sup>®</sup> graft was a 7-year-old Thoroughbred gelding. Due to the apparent depth of their corneal lesions, three patients received a frozen corneal graft to replace missing corneal tissue, which was then covered with a single-layer ACell<sup>®</sup> graft: a 5-month-old Thoroughbred colt, a 17-year-old Welsh Cob gelding, and an 18-year-old Thoroughbred mare. Corneal donor tissue had been harvested from horses humanely euthanized for nonocular disease immediately following euthanasia, sectioned in half-cornea aliquots, and frozen in a triple antibiotic solution of neomycin, polymyxin-B, and gramicidin until use. During surgery, one patient, a 10-year-old Thoroughbred gelding, required an intraocular injection of tissue plasminogen activator to lyse fibrin which had accumulated in the anterior chamber.

#### Postoperative therapy

With addition of systemic antimicrobials for 24 h after surgery, postoperative medical management closely reflected pre-operative: topical ofloxacin, voriconazole, autologous serum, and atropine, as well as topical cefazolin if bacterial cocci were noted on corneal cytology, with flunixin meglumine as a systemic nonsteroidal anti-inflammatory, initially dosed at 1.1 mg/kg q12h and with dose decreasing based on clinical signs as well as laboratory findings suggestive of gastrointestinal or renal NSAID toxicity such as hypoproteinemia or azotemia. Fourteen patients retained a complete temporary tarsorrhaphy for 3–5 days, at which time a single suture was removed to allow evaluation of globe integrity, peripheral corneal and anterior chamber clarity, as well as pupil size. Remaining partial tarsorrhaphy sutures were removed between 14 and 21 days postoperatively. Partial tarsorrhaphies were left in place to improve corneal comfort, provide structural support to the surgical site, and increase corneal contact time of topical medications.

Three patients were discharged from the hospital 1–2 days postoperatively with a complete tarsorrhaphy in place. One was an otherwise healthy 4-month-old Standardbred colt who returned to the care of the breeding farm veterinarian to minimize exposure to nosocomial pathogens. The second was a 14-year-old Standardbred stallion whose temperament was not suited for hospitalization. The complete tarsorrhaphy was left in place for 3 weeks in these two patients, until return to the hospital for a recheck examination by a boarded veterinary ophthalmologist. The third patient discharged with a complete tarsorrhaphy 2 days postoperatively was a 7-year-old Friesian gelding who was discharged against medical advice for economic reasons.

Approximately 2 weeks postoperatively, keratouveitis was noted in the 14 patients who were reexamined at that time. This was temporally associated with a decrease in flunixin meglumine dosing to approximately 0.25–0.5 mg/kg/day in all cases. Keratouveitis resolved in all 14 patients with increases in dose and frequency of systemic nonsteroidal anti-inflammatory medication.

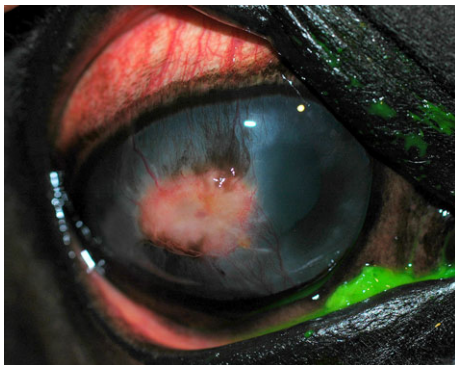
#### Outcome

Follow-up information was obtained for all 17 patients. Figures 1–7 show the clinical course of two uncomplicated cases, the 13-year-old Standardbred stallion and a 15-year-old Warmblood gelding, respectively. One eye had been enucleated 11 days postoperatively and was excluded from further analysis. For the remaining 16 eyes, topical medications were discontinued from 5 to 8 weeks postoperatively, and at the time topical medications were discontinued, all 16 eyes were visual, as determined by positive direct/indirect PLRs, dazzle reflex, and location-dependent menace response, and were structurally sound, although all developed mild to severe fibrotic scarring at the graft site. Considering all cases included in this study, 16/17 eyes (94%) retained acceptable functional vision and required no further medication. Figures 3, 6, and 7 show the variable extent of ACell<sup>®</sup> opacification *in situ*. The graft material appeared to have encouraged neovascularization in all eyes.

The patient that had the operated eye enucleated was a 7-year-old Friesian gelding who had been presented with advanced, preexisting chronic renal disease severely complicating medical management by limiting the use of flunixin meglumine. Two days postoperatively, this patient was discharged from the hospital against medical advice due to the severity of ocular as well as systemic disease. Financial constraints not evident at the time of surgery were responsible for discharge from hospital. Eleven days postoperatively, the horse was readmitted with a complaint of an iris prolapse in the operated eye, which was enucleated rather than repaired, again due to financial limitations. Corneal disease severity, as well as systemic disease which limited pre- and postoperative anti-inflammatory

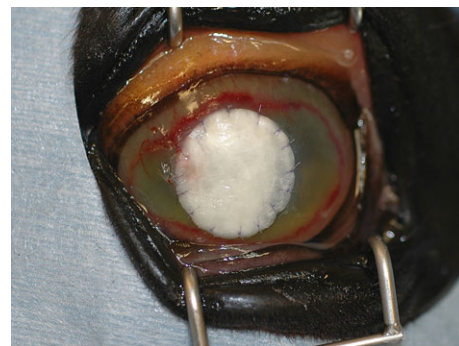

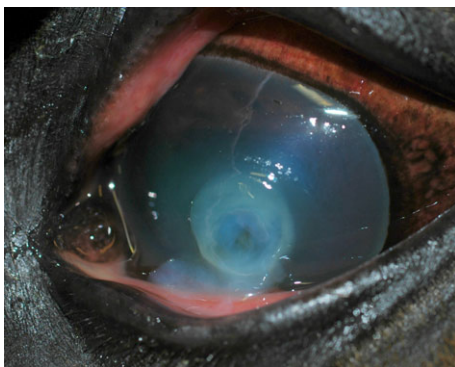Figure 2. Case shown in Fig. 1, intra-operative ACell<sup>®</sup> graft.



**Figure 3.** Case shown in Fig. 1, 6 weeks postoperatively following ACell<sup>®</sup> graft. There is a horizontally oval axial region of granulation tissue at the site of the original fungal plaque, surrounded by fibrosis at suture sites and pigmentation in bands extending from the limbus axially toward the granulation tissue. There was no fluorescein uptake at this time.

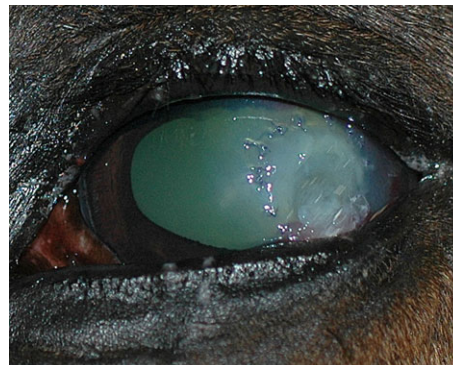

**Figure 4.** Pre-operative catastrophic cornea in 15-year-old Warmblood gelding, from mixed bacterial–fungal infectious keratitis (*Pseudomonas* and *Aspergillus*) refractory to medical treatment. There was a round axial melting ulcer with a dark center representing severe stromal melting and loss. There was no vascularization in this cornea which was treated aggressively prior to referral with a topical nonsteroidal anti-inflammatory drug. Malacic cornea was noted streaming from the center of the ulcer over the unaffected cornea inferior to it toward the eyelid margin, and when the eyelids were closed, this stream of malacic cornea protruded between the eyelids.

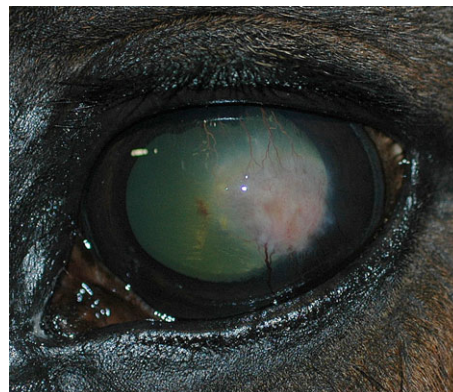
therapy, may have contributed to failure and enucleation in this case.

## DISCUSSION

In this retrospective study of surgical repair of severe keratomalacia with ACell<sup>®</sup> grafts, 94% of affected corneas had successful outcomes. Because only horses with corneal lesions repaired using ACell<sup>®</sup> graft were considered in this study, a direct comparison between surgical repair with ACell<sup>®</sup> vs. conjunctival or amnion grafts is not possible, but length of medical therapy and visual outcome in this study did not appear subjectively to differ from patients with severe keratomalacia repaired using conventional



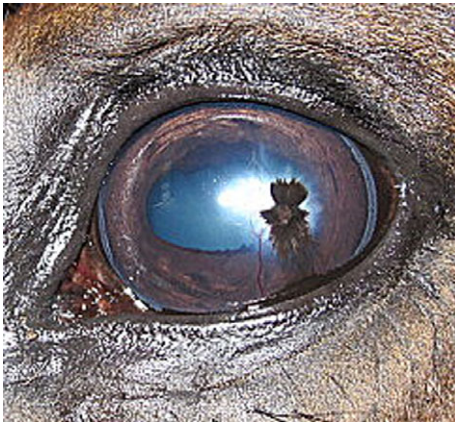**Figure 5.** Case shown in Fig. 4, positive fluorescein uptake only around graft sutures, 18 days postoperatively at tarsorrhaphy removal. The area encircled by sutures was clear enough to see through cornea into the anterior chamber. Vascularization extended from the inferotemporal limbus axially.



**Figure 6.** Case shown in Fig. 4, vascular scar at 6 weeks postoperatively. Vascularization and fibrosis have extended axially to occupy the center of the corneal opacity, with several larger caliber vessels still prominent.

biomaterials such as a conjunctival pedicle or amniotic membrane grafts. Corneal pigmentation and fibrosis in the patients treated with an ACell<sup>®</sup> graft in this study appeared subjectively similar to that resulting from repair with amnion grafts, but again, no direct comparison can be made. However, a subjective comparison of corneal clarity following ACell<sup>®</sup> vs. conjunctival graft suggests that the former may lead to an improved visual and cosmetic outcome, because the extracellular matrix degrades as local tissues replace the graft, whereas the conjunctival graft in many cases remains opaque. Both biomaterials may encourage neovascularization, but it appeared subjectively to be less significant with ACell<sup>®</sup> graft. The absorbable suture material used to secure the graft in place likely contributes to the vascularization response. This may be particularly important for grafts with a large surface area, in which eyes may be functionally blinded by the dense scarring associated with conjunctival grafts. With subjectively similar outcomes to amnion in terms of optical





**Figure 7.** Case shown in Fig. 4, pigmented scar at 10 weeks. The horizontal oval axial region of the cornea corresponding to the original ulcer had become fairly clear, with only a focal region of fibrosis. Pigmentation from the inferotemporal limbus toward the lesion developed in a vertical band but should not compromise vision.

clarity and cosmesis, the main advantage of ACell<sup>®</sup> graft as a biomaterial over amnion would be commercial availability and room temperature shelf storage.

Only one patient experienced failure of the ACell<sup>®</sup> graft and subsequent loss of the affected eye. This unfavorable outcome may not have resulted directly from failure of the ACell<sup>®</sup> corneal disc, but rather indirectly from renal disease and financial constraints which complicated medical management. This case reinforces the necessity of consistent, aggressive topical and systemic medical management to support successful surgical repair using any biomaterial.

Keratouveitis noted about 2 weeks postoperatively may represent an overly aggressive protocol for decreasing systemic nonsteroidal anti-inflammatory therapy, which is done to address concerns about gastrointestinal and renal toxicity associated with systemic nonsteroidal anti-inflammatory use, particularly flunixin meglumine, in horses. Without a direct comparison of postoperative disease progression between ACell<sup>®</sup> and other biomaterials such as conjunctival or amnion grafts, attributing postoperative keratouveitis to the biomaterial can remain only speculative. However, a key difference between acellular matrix products such as ACell<sup>®</sup> and cellular biomaterials such as conjunctival and amnion grafts is that the former is reabsorbed by the body, leaving no permanently transplanted tissue behind. The extracellular matrix supports regrowth of the host tissue, rather than replacement of tissue with fibrosis. It may be the case that the regenerative process stimulates more inflammation as the matrix is being reabsorbed than the incorporation of a biomaterial such as conjunctiva or amnion into the corneal defect.

Based on results of this study, extracellular matrix grafts may be a viable alternative to other biomaterials such as amnion and conjunctival for corneal grafting in equids, with the advantages of commercial availability and shelf

storage relative to amnion, and improved corneal clarity relative to conjunctival grafts. An objective quantitative measurement of corneal clarity and visual outcome, as well as a direct comparison of the different biomaterials within the same patient population, would be required to draw a more definitive conclusion.

## REFERENCES

- Hakanson N, Merideth R. Conjunctival pedicle grafting in the treatment of corneal ulcers in the dog and cat. *The Journal of the American Animal Hospital Association* 1987; **23**: 641–648.
- Johnson W. On four cases of cornea-grafting. *British Medical Journal* 1886; **2**: 1209.
- Wood CA. *A System of Ophthalmic Operations*. Cleveland Press, Chicago, 1911.
- Henriksen Mde L, Plummer CE, Mangan B *et al*. Visual outcome after corneal transplantation for corneal perforation and iris prolapse in 37 horses: 1998–2010. *Equine Veterinary Journal. Supplement* 2012; **43**: 115–119.
- Brooks DE. Complications of ophthalmic surgery in the horse. *The Veterinary Clinics of North America. Equine Practice* 2008; **24**: 697–734, x.
- Ollivier FJ, Kallberg ME, Plummer CE *et al*. Amniotic membrane transplantation for corneal surface reconstruction after excision of corneolimbic squamous cell carcinomas in nine horses. *Veterinary Ophthalmology* 2006; **9**: 404–413.
- Barros PS, Safatle AM, Godoy CA *et al*. Amniotic membrane transplantation for the reconstruction of the ocular surface in three cases. *Veterinary Ophthalmology* 2005; **8**: 189–192.
- Lassaline ME, Brooks DE, Ollivier FJ *et al*. Equine amniotic membrane transplantation for corneal ulceration and keratomalacia in three horses. *Veterinary Ophthalmology* 2005; **8**: 311–317.
- Lewin GA. Repair of a full thickness corneoscleral defect in a German shepherd dog using porcine small intestinal submucosa. *Journal of Small Animal Practice* 1999; **40**: 340–342.
- Featherstone HJ, Sansom J, Heinrich CL. The use of porcine small intestinal submucosa in ten cases of feline corneal disease. *Veterinary Ophthalmology* 2001; **4**: 147–153.
- Bussieres M, Krohne SG, Stiles J *et al*. The use of porcine small intestinal submucosa for the repair of full-thickness corneal defects in dogs, cats and horses. *Veterinary Ophthalmology* 2004; **7**: 352–359.
- Gionfriddo JR, Powell CC. Primary closure of the corneas of two Great Horned owls after resection of nonhealing ulcers. *Veterinary Ophthalmology* 2006; **9**: 251–254.
- Mannis MJ, Krachmer JH. Keratoplasty: a historical perspective. *Survey of Ophthalmology* 1981; **25**: 333–338.
- Bigger SL. Proceedings of the Royal Irish Academy. *Dublin Journal of Medical Science (1836–1845)* 1837; **11**: 408–417.
- Paton RT. History of corneal transplantation. *International Ophthalmology Clinics* 1970; **10**: 181–186.
- Parshall CJ. Lamellar corneal-scleral transposition. *Journal of the American Animal Hospital Association* 1973; **9**: 270–277.
- Brightman AH, McLaughlin SA, Brogdon JD. Autogenous lamellar corneal grafting in dogs. *Journal of the American Medical Association* 1989; **195**: 469–475.
- Hacker D. Frozen corneal grafts in dogs and cats: a report on 19 cases. *The Journal of the American Animal Hospital Association* 1991; **27**: 119–123.

19. Brooks D. Targeted lamellar keratoplasty in the horse: a paradigm shift in equine corneal transplantation. *Equine Veterinary Journal* 2010; **42**: 24–30.
20. Soontornvipart K, Tuntivanich N, Kecova H *et al*. Conjunctival pedicle graft in dogs and cats: a retrospective study of 88 cases. *Acta Veterinaria Brno* 2003; **72**: 63.
21. Collins MB, Ethell MT, Hodgson DR. Management of mycotic keratitis in a horse using a conjunctival pedicle graft. *Australian Veterinary Journal* 1994; **71**: 298–299.
22. Utter M, Wotman K, Armour M *et al*. Clinical findings and outcomes of ulcerative keratomycosis in 30 horses in the mid-Atlantic United States (2006–2007). *Equine Veterinary Education* 2010; **22**: 31–39.
23. Vanore M, Chahory S, Payen G *et al*. Surgical repair of deep melting ulcers with porcine small intestinal submucosa (SIS) graft in dogs and cats. *Veterinary Ophthalmology* 2007; **10**: 93–99.